

# Piroxicam, Mitoxantrone, and Coarse Fraction Radiotherapy for the Treatment of Transitional Cell Carcinoma of the Bladder in 10 Dogs: A Pilot Study

Ten dogs with transitional cell carcinoma (TCC) of the bladder were treated with a combination of once-weekly coarse fraction radiation therapy (six weekly fractions of 5.75 Gray [Gy]), mitoxantrone chemotherapy, and piroxicam. All dogs completed the radiation therapy protocol, and only minimal side effects were observed. Only two (22%) dogs achieved a measurable partial response; however, 90% of the dogs had amelioration of their urinary clinical signs. The median survival time for all dogs was 326 days. While this treatment protocol was well tolerated, the response rate and overall survival duration was not superior to reports using mitoxantrone and piroxicam without radiation therapy in dogs with TCC. *J Am Anim Hosp Assoc* 2004;40:131–136.

Valerie J. Poirier, DMV

Lisa J. Forrest, VMD,  
Diplomate ACVR  
(Radiology, Radiation Oncology)

William M. Adams, DVM,  
Diplomate ACVR  
(Radiology, Radiation Oncology)

David M. Vail, DVM, MS,  
Diplomate ACVIM (Oncology)

RS

## Introduction

Transitional cell carcinoma (TCC) is the most common neoplasm of the urinary bladder in dogs, accounting for 1% of all canine neoplasms. At initial clinical presentation, 82% to 98% of TCCs have infiltrated the muscle layer; 14% to 17% have already metastasized; and most are located in the trigone region, making surgical excision difficult or impossible.<sup>1-4</sup>

Several treatments have been investigated for TCC in dogs, generally with limited success. Cystectomy with ureterocolonic anastomosis has been reported, but it is associated with severe side effects (i.e., hyperammonemia, hyperchloremia, metabolic acidosis, uremia, and pyelonephritis) and short survival times of <5 months.<sup>5</sup> Partial cystectomy or surgical debulking has a high occurrence of local and distant tumor relapse and median survival times between 3 and 10 months.<sup>2,6,7</sup> Transitional cell carcinoma is relatively chemoresistant. Cisplatin,<sup>8-10</sup> doxorubicin,<sup>6</sup> and mitoxantrone<sup>11</sup> have shown some efficacy, but response rates are usually <25%, and median survival times are reported to be between 4 and 9 months. Radiation therapy (full course or intraoperative) has been used with some efficacy (e.g., with median survival times of 4 to 16 months); however, complications of therapy included urinary incontinence, cystitis, and accompanying stranguria, and have resulted in euthanasia of many of the cases. Bladder fibrosis is also a common feature at necropsy.<sup>2,12,13</sup>

Piroxicam, a nonsteroidal anti-inflammatory drug, may improve clinical signs in dogs with TCC. In one report, an objective tumor response (i.e., reduction in size) was seen in six of 34 treated dogs, with a median survival time of 6 months.<sup>14</sup> Piroxicam's mechanism of action is not completely understood, but it may result from immunomodulatory, proapoptotic, and antiangiogenic effects rather than from a direct cytotoxic effect.<sup>3,15</sup> Piroxicam is generally well tolerated. Gastrointestinal toxicity is the most common side effect and occurs in approximately 15%

From the School of Veterinary Medicine  
and the Comprehensive Cancer Center,  
University of Wisconsin-Madison,  
2015 Linden Drive,  
Madison, Wisconsin 53706.

of treated cases.<sup>3,14</sup> Recently, a combination of piroxicam and mitoxantrone chemotherapy was used in dogs with TCC and resulted in a higher response rate (34.5% versus 16.3%) than what was observed when piroxicam was used as a single agent.<sup>16</sup>

In humans, only 25% of TCCs are classified as invasive at the time of diagnosis, and therapy is divided into two categories: sparing and nonsparing of the bladder. Unfortunately, in veterinary medicine, cystectomy has been associated with severe complications and little therapeutic gain,<sup>5</sup> probably because of the advanced nature of the disease in dogs at the time of diagnosis. Regarding bladder-sparing treatment options in humans, radiation therapy alone (i.e., external beam, implantation, intraoperative) or in combination with surgery (i.e., partial cystectomy) and chemotherapy (i.e., concurrent, alternating, sequential), is the treatment strategy favored in the most recent protocols. However, the optimal radiation protocol is still unknown in people.<sup>17</sup>

The purpose of this pilot study was to evaluate a multimodality protocol consisting of coarse fraction radiation therapy (extrapolated from a protocol used in human cancer patients) in combination with mitoxantrone and piroxicam for TCC of the bladder in dogs.<sup>18</sup>

## Materials and Methods

### Case Material

Medical records of dogs with histopathologically (n=8) or cytopathologically (n=2) confirmed TCC of the bladder, presented to the University of Wisconsin-Madison Veterinary Medical Teaching Hospital from 1997 to 2000, were retrospectively reviewed. Dogs were included in the study if they had been treated with coarse fraction radiation therapy, mitoxantrone chemotherapy, and piroxicam, and if follow-up information was available. Information obtained from medical records included signalment, clinical signs, duration of clinical signs, clinical stage, previous surgery, treatment toxicity, response to therapy, date of progression of disease, and date of death. Cause of death or reason for euthanasia was obtained from the medical record when available or through conversations with the client. Diagnostic evaluation and clinical staging included a complete blood count (CBC), serum biochemical profile, urinalysis, thoracic radiographs, and an abdominal ultrasound.

### Radiation Therapy

Dogs were treated using a cobalt<sup>60</sup> external-beam isocentric radiotherapy unit.<sup>a</sup> The total prescribed dose of radiation was 34.5 Gray (Gy) given in six weekly fractions of 5.75 Gy. Treatment consisted of two lateral, parallel-opposed, equally weighted fields that included the whole bladder. The cranial abdomen and pelvis were blocked when within the field. Portal radiography documented field positioning at each treatment, and nongraphic (i.e., manual) planning was used in all cases.

### Chemotherapy

Mitoxantrone<sup>b</sup> was given intravenously at an initial dose of 5 mg/m<sup>2</sup> with subsequent dose reduction if toxicity was

observed. A CBC was performed 1 week after the first chemotherapy treatment and prior to each subsequent treatment. Treatment was repeated *q* 21 days for at least two treatments or until progression of disease was noted. Chemotherapy occurring in the first 6 weeks of the protocol was administered concurrently with radiation therapy (i.e., on the same morning). Piroxicam<sup>c</sup> was administered orally at a dose of 0.3 mg/kg, once daily indefinitely.

### Follow-up

All dogs had an initial follow-up abdominal ultrasound performed on the day of their last radiation therapy. Follow-up abdominal ultrasonography was recommended *q* 4 to 8 weeks until progression of disease was noted. Follow-up information was obtained by review of the animal's medical record or by telephone communication with the referring veterinarian or the client. Response was determined using ultrasonography and a two-dimensional measurement of the largest portion of the mass. Response was defined as complete response (complete regression of all measurable disease), partial response (>50% but <100% regression of measurable disease), minimal response (>25% but <50% regression of measurable disease), stable disease (no change or <25% progression), and progressive disease (>25% increase in measurable disease).

### Toxicity Assessment

Toxicity of the radiation therapy protocol was assessed through review of the weekly patient record, maintained during the 6-week radiation therapy course, and the outcome as reported by the client at subsequent visits. Acute and late radiation effects were assessed and scored according to the Veterinary Radiation Therapy Oncology Group (VROG) standard.<sup>19</sup> Toxicity resulting from mitoxantrone chemotherapy was determined by CBC and medical history at each visit. Neutropenia and thrombocytopenia were classified using National Cancer Institute parameters.<sup>d</sup>

### Statistical Analysis

Time to progression was defined as the time (in days) from the first radiation treatment to the time when progressive disease was noted on ultrasonography. Duration of response was defined as the time from achievement of response until detection of subsequent progression of disease on ultrasonography, or loss to follow-up, or death. Overall survival was defined as the time (in days) from the first radiation treatment until death. Survival curves for time to progression and overall survival were generated using the Kaplan-Meier product-limit method.<sup>e</sup> Data was censored if dogs were alive at the end of the study, were lost to follow-up, or died of disease unrelated to TCC. All dogs were included in analysis, whether they received all prescribed treatments or not.

## Results

### Case Data

Ten dogs met the criteria for inclusion in the study. Five were spayed females, and five were neutered males. Nine

breeds were represented, including the Shetland sheepdog (n=2), Labrador retriever, golden retriever, Australian terrier, Australian heeler, miniature poodle, miniature schnauzer, West Highland white terrier, and a collie mixed-breed dog. The median age was 9.5 years (range, 8 to 13 years), and the median weight was 15.3 kg (range, 6.2 to 34 kg). Presenting clinical signs included hematuria (10/10), pollakiuria (7/10), stranguria (3/10), and urinary incontinence (2/10). Clinical signs were present from 1 week to 6 months before diagnosis, with a median of 3 months.

### Staging and Previous Therapy

None of the dogs had clinical, radiographic, or ultrasonographic evidence of metastases at the time of diagnosis. All but one of the tumors were stage T2 (i.e., all had evidence of invasion of the bladder wall).<sup>20</sup> Case no. 2 was considered noninvasive on histopathology (stage T1). Tumors were located in the bladder trigone in seven dogs, in the midbody of the bladder in two dogs, and in the cranial portion of the bladder in one dog. The three dogs with nontrigonal tumors underwent partial cystectomy (21, 60, and 156 days prior to radiation therapy). Two of the three dogs had recurrent macroscopic disease, and one had microscopic disease based on ultrasonographic evaluation at the initiation of radiotherapy. Four dogs were started on piroxicam prior to radiation therapy (median, 5 weeks; range, 1 to 48 weeks). One dog received one treatment of photodynamic therapy 56 days prior to the start of the radiation therapy, without response [see Table].

### Radiation Therapy and Toxicity

All dogs completed the prescribed radiation treatment. Only one dog experienced acute effects of radiation therapy, including self-limiting, grade 1 dermatitis that consisted of erythema and dry desquamation. Late side effects of radiation therapy occurred in four dogs and consisted of cutaneous hyperpigmentation in the radiation therapy field (n=1) and urinary incontinence (n=3).

### Chemotherapy and Toxicity

Dogs received between one and seven mitoxantrone (median, four) treatments. Mitoxantrone was generally well tolerated. Four dogs experienced vomiting, one dog had diarrhea, and three dogs developed neutropenia (grade 2; neutrophil count,  $1.0$  to  $1.5 \times 10^3/\mu\text{L}$ ). All side effects were self-limiting, and no dogs required hospitalization. Five dogs had their subsequent mitoxantrone dose reduced by 20% because of toxicity (gastrointestinal toxicity [n=2] and neutropenia [n=3]). All but one dog received piroxicam daily. This dog developed lethargy and vomiting, which was attributed to piroxicam that was administered prior to the start of radiation therapy, and the owner declined resumption of the drug.

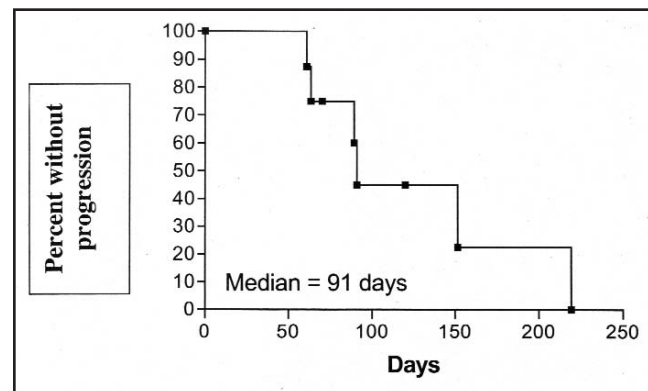
### Response and Survival

Nine of 10 dogs had clinical amelioration of their urinary tract signs. An accurate duration of this amelioration of signs could not be determined from the records. Two dogs

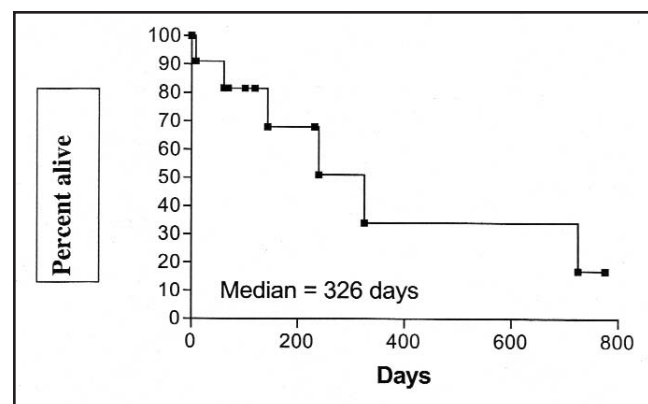
had a partial response, five dogs had stable disease (two had a minimal response), and two dogs had progressive disease as determined by ultrasonography performed at the time of their last radiation therapy. Progression was determined for all dogs except one (case no. 1) by subsequent ultrasonographic examinations. The overall median time to progression for dogs with stable disease or partial responses was 91 days (range, 61 to 219 days; Figure 1). After progression of disease, three dogs received additional chemotherapy: doxorubicin (n=1); doxorubicin, cisplatin, and gemcitabine (n=1); and carboplatin (n=1). Only one dog (case no. 2) had a partial response to doxorubicin. The median overall survival time was 326 days (range, 9 to 775 days; Figure 2). Five dogs died of progressive TCC; one died of acute collapse; one died of hepatic fibrosis; one died of septicemia following carboplatin administration; one was alive at 775 days; and one dog was lost to follow-up at 120 days.

### Discussion

Transitional cell carcinoma of the bladder is usually found in older dogs. The signalments of the dogs in this study are



**Figure 1**—Kaplan-Meier time to progression curve for dogs with transitional cell carcinoma of the urinary bladder that were treated with coarse fraction radiation therapy, mitoxantrone chemotherapy, and piroxicam. The median time to progression was 91 days.



**Figure 2**—Kaplan-Meier survival curve for dogs with transitional cell carcinoma of the urinary bladder that were treated with coarse fraction radiation therapy, mitoxantrone chemotherapy, and piroxicam. The median survival time was 326 days.

**Table**  
Signalment, Treatment, Toxicity, Response, and Outcome in 10 Dogs With Transitional Cell Carcinoma of the Bladder

Case No.	Signalment*	Prior Therapy	Radiation Treatments/ Toxicity	Mitoxantrone Treatments/ Toxicity	Response†	TTP‡ (d)	Overall Survival (d)	Outcome
1	Miniature schnauzer, 13 y, FS, 15 kg	Partial cystectomy	6 × 5.75 Gy	3/vomiting, diarrhea	SD	Unknown	61	Dead due to tumor; no piroxicam
2	West Highland white terrier, 9 y, MN, 10 kg	Partial cystectomy; piroxicam x 4 wks	6 × 5.75 Gy/ hyperpigmentation, urinary incontinence	2/neutropenia	PD	NA	726	Dead due to tumor; received adriamycin, cisplatin, and gemcitabine postprogression
3	Shetland sheepdog, 10 y, MN, 15 kg	Piroxicam x 48 wks; photodynamic therapy	6 × 5.75 Gy	2	PD	NA	239	Dead; received one dose of adriamycin postprogression
4	Golden retriever, 10 y, MN, 34 kg		6 × 5.75 Gy/ urinary incontinence	4/neutropenia, vomiting	SD	89	145	Dead due to tumor
5	Collie mixed-breed, 11 y, MN, 32 kg	Partial cystectomy (microscopic)	6 × 5.75 Gy	5	NA	91	100	Dead due to septic episode postcarboplatin
6	Miniature poodle, 9 y, FS, 6 kg	Piroxicam x 1 wk	6 × 5.75 Gy/ urinary incontinence	3/neutropenia	SD (MR)	63	326	Dead due to tumor
7	Australian terrier, 8 y, FS, 6 kg	Piroxicam x 6 wks	6 × 5.75 Gy/ mild dermatitis	5	PR	70	70	Dead due to hepatic disease; small TCCs at necropsy
8	Labrador retriever, 8 y, FS, 29 kg		6 × 5.75 Gy	7/vomiting	SD	219	775	Alive
9	Australian heeler, 11 y, FS, 18 kg		6 × 5.75 Gy	5	PR	120	120	Lost to follow-up
10	Sheltie, 8 y, FS, 15 kg		6 × 5.75 Gy	4	SD (MR)	152	232	Dead due to collapse

\* FS=female spayed; MN=male neutered

† SD=stable disease; PD=progressive disease; NA=not available; MR=minimal response; PR=partial response

‡ TTP=time to progression

§ TCC=transitional cell carcinoma

consistent with previous reports, with the exception of the male to female ratio (1:1 compared to 1:1.7 and 1:1.9 in previous reports<sup>2,3</sup>).

Bladder-sparing treatment options in humans with advanced TCC usually employ a multimodality approach (e.g., combination of radiation therapy and chemotherapy followed by surgery). The purpose of this study was to evaluate the toxicity and potential efficacy of a multimodality approach in the treatment of TCC in dogs. Mitoxantrone was chosen as the protocol to be employed in this study based on a partial response demonstrated for canine TCC in a phase I study.<sup>11</sup> Piroxicam was chosen because of its proven antitumor activity in canine TCC.<sup>3,14</sup> The radiation therapy protocol was chosen based on its use and success in advanced disease in humans.<sup>18</sup>

Side effects related to the coarse fractionation radiation protocol employed in this study were mild and self-limiting. Of the dogs that developed urinary incontinence, all three developed urinary incontinence after progression of their disease, so it was not possible to determine if this was radiation-induced or a result of tumor progression. Only one dog was necropsied, and no evidence of bladder fibrosis was observed. Overall, the radiation therapy protocol was well tolerated, even with the large dose per fraction (5.75 Gy) administered. The authors' radiotherapy protocol was associated with less late complications than a recent report utilizing a protocol with a similar fraction size for pelvic irradiation to treat various tumors.<sup>21</sup> No cystitis or colitis could be attributed to the radiation used in the study reported here. This was unexpected, since late effects are usually related to the size of the fraction as well as the total dose of radiation given. In the present study, the total dose was relatively modest (34.5 Gy), but the dose per fraction (5.75 Gy) was elevated, so more late effects were expected. Since the median survival time was 326 days with some dogs censored early, it is possible that they did not live long enough to develop late effects.

Five dogs had their mitoxantrone dose reduced because of toxicity, which was higher than what has been previously reported.<sup>16,22,23</sup> This could be related to combination therapy with piroxicam, although in Henry, *et al.*,<sup>16</sup> only four of 55 dogs required a dose reduction. The weekly anesthesia used in the present study for radiation therapy might also be a cause for increased toxicity. Owner reluctance to accept toxicity (even though the toxicity was acceptable by most oncologists' standards) might also have led to the clinician lowering the dose. Also, the radiation administered may have made the dogs more sensitive to the side effects of chemotherapy.

Survival times were affected by competing causes of death and by use of additional, subsequent therapies in these dogs. Time to progression might be a more meaningful measure of this protocol's efficacy. Most dogs (90%) had amelioration of their clinical signs, despite a low measurable objective response rate (22%). This amelioration is similar to that achieved with the use of single-agent piroxicam in dogs with TCC.<sup>3,14</sup> The dog (case no. 1) that did not show

amelioration of his clinical signs was also the dog that did not receive piroxicam because of prior toxicity. The 90% subjective rate of improvement in clinical signs, along with a median progression-free survival time of 91 days and median survival time of 326 days, are similar to rates in a recent study of dogs with TCC treated with mitoxantrone and piroxicam without radiotherapy.<sup>16</sup> This implies that the addition of radiotherapy, of the type and fraction protocol utilized in this study, did not enhance overall responsiveness.

The limitations of this study include its retrospective nature, the small number of cases, and the lack of standardization of follow-up. Other than the abdominal ultrasonography performed at the end of radiation therapy for all dogs, timing of subsequent ultrasound examinations was dependent upon both the client and the clinician. Additionally, abdominal ultrasonography was not performed by only one person, so there may have been variability in interpretations between ultrasonographers. An effort was made to have a full bladder at the time of each ultrasound study.

Unfortunately, it is not possible to determine the efficacy of each of the components of this multimodality therapeutic protocol. Surgery was performed on three dogs in this series prior to radiation therapy, and one dog had microscopic disease at the time of the radiation therapy; therefore, response to therapy could not be evaluated in this case. However, early recurrence of the TCC (at 3 months) was documented in postradiation therapy follow-up of this dog (case no. 5). Since this dog died of complications from carboplatin chemotherapy, it was not possible to determine if he would have enjoyed a longer survival time than dogs treated in the macroscopic setting. The benefit of piroxicam has been proven,<sup>3,14</sup> and it likely was involved in the amelioration of clinical signs observed in most of the dogs in this series. Also of note, was that four dogs were already on piroxicam at the time of presentation to the authors' institution. However, it was not possible to determine the response to single-agent piroxicam from an overall review of the medical records in this study.

## Conclusion

Although well tolerated, the coarse fractionation therapy protocol employed in this study did not result in enhanced response rates or duration of tumor control when compared to results from a previous study of dogs treated with mitoxantrone and piroxicam without radiotherapy.<sup>16</sup>

---

<sup>a</sup> Theratron 780; Atomic Energy of Canada Ltd., Kanata, Ontario, Canada

<sup>b</sup> Novantrone; Immunex Corporation, Seattle, WA

<sup>c</sup> Feldene; Pfizer, New York, NY

<sup>d</sup> National Cancer Institute. Common toxicity criteria, version 2.0. March 23, 1998

<sup>e</sup> Prism 4.0 Graph Pad Software, San Diego, CA

---

## References

1. Osborne CA, Low DG, Perman V, *et al.* Neoplasms of the canine and feline urinary bladder: incidence, etiologic factors, occurrence and pathologic features. *Am J Vet Res* 1968;29:2041-2055.

2. Norris AM, Laing EJ, Valli VE, *et al.* Canine bladder and urethral tumors: a retrospective study of 115 cases (1980-1985). *J Vet Intern Med* 1992;6:145-153.
  3. Knapp DW, Glickman NW, DeNicola DB, *et al.* Naturally-occurring canine transitional cell carcinoma of the urinary bladder: a relevant model of human invasive bladder cancer. *Urol Oncol* 2000;5:47-59.
  4. Valli VE, Norris A, Jacobs RM, *et al.* Pathology of canine bladder and urethral cancer and correlation with tumour progression and survival. *J Comp Path* 1995;113:113-130.
  5. Stone EA, Withrow SJ, Page RL, *et al.* Ureterocolonic anastomosis in ten dogs with transitional cell carcinoma. *Vet Surg* 1988;17:147-153.
  6. Helfand SC, Hamilton TA, Hungerford LL, *et al.* Comparison of three treatments for transitional cell carcinoma of the bladder in dogs. *J Am Anim Hosp Assoc* 1994;30:270-275.
  7. Stone EA, George TF, Gilson SD, *et al.* Partial cystectomy for bladder neoplasia: surgical technique and outcome of 11 dogs. *J Small Anim Pract* 1996;37:480-485.
  8. Chun R, Knapp DW, Widmer WR, *et al.* Cisplatin treatment of transitional cell carcinoma of the urinary bladder in dogs: 18 cases (1983-1993). *J Am Vet Med Assoc* 1996;9:1588-1592.
  9. Moore AS, Cardona A, Shapiro W, *et al.* Cisplatin (cisdiamminedichloroplatinum) for treatment of transitional cell carcinoma of the urinary bladder or urethra: a retrospective study of 15 dogs. *J Vet Intern Med* 1990;4:148-152.
  10. Shapiro W, Kitchell BE, Fossum TW, *et al.* Cisplatin for treatment of transitional cell and squamous cell carcinomas in dogs. *J Am Vet Med Assoc* 1988;193:1530-1533.
  11. Ogilvie GK, Obradovich JE, Emslie RE, *et al.* Efficacy of mitoxantrone against various neoplasms in dogs. *J Am Vet Med Assoc* 1991;198:1618-1621.
  12. Walker M, Breider M. Intraoperative radiotherapy of canine bladder cancer. *Vet Radiol* 1987;28:200-204.
  13. Withrow SJ, Gillette EL, Hoopes PJ, *et al.* Intraoperative irradiation of 16 spontaneously occurring canine neoplasms. *Vet Surg* 1989;18:7-11.
  14. Knapp DW, Richardson RC, Chan TCK, *et al.* Piroxicam therapy in 34 dogs with transitional cell carcinoma of the urinary bladder. *J Vet Intern Med* 1994;8:273-278.
  15. Mohammed SI, Bennett PF, Craig BA, *et al.* Effects of the cyclooxygenase inhibitor, piroxicam, on tumor response, apoptosis, and angiogenesis in canine model of human invasive urinary bladder cancer. *Canc Res* 2002;62:356-358.
  16. Henry CJ, McCaw DL, Turnquist SE, *et al.* Clinical evaluation of mitoxantrone and piroxicam in a canine model of human invasive urinary bladder carcinoma. *Clin Canc Res* 2003;9(2):906-911.
  17. Herr HW, Shipley WU, Bajorin DF. Cancer of the bladder. In: DeVita VT, Hellman S, Rosenberg SA, eds. *Cancer: Principles & Practice of Oncology*. 6th ed. Philadelphia: Lippincott Williams & Wilkins, 2001:1396-1415.
  18. Rostom AY, Tahir S, Gershuny AR, *et al.* Once weekly irradiation for carcinoma of the bladder. *Int J Rad Oncol Biol Phys* 1996;35:289-292.
  19. Ladue T, Klein MK. Toxicity criteria of the veterinary radiation therapy oncology group. *Vet Radiol Ultrasound* 2001;42(5):475-476.
  20. Owen LN. TNM classification of tumors in domestic animals. Geneva: World Health Organization, 1980:34.
  21. Anderson CR, McNiel EA, Gillette EL, *et al.* Late complication of pelvic irradiation in 16 dogs. *Vet Radiol Ultrasound* 2002;43(2):187-192.
  22. Ogilvie GK, Moore AS, Chen C, *et al.* Toxicoses associated with the administration of mitoxantrone to dogs with malignant tumors: a dose escalation study. *J Am Vet Med Assoc* 1994;205:570-573.
  23. Ogilvie GK, Obradovich JE, Emslie RE, *et al.* Toxicoses associated with administration of mitoxantrone to dogs with malignant tumors. *J Am Vet Med Assoc* 1991;198:1613-1617.
-